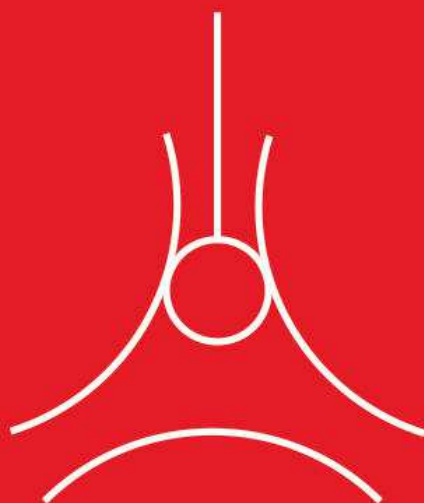

## FETAL ENDOSCOPIC TRACHEAL OCCLUSION

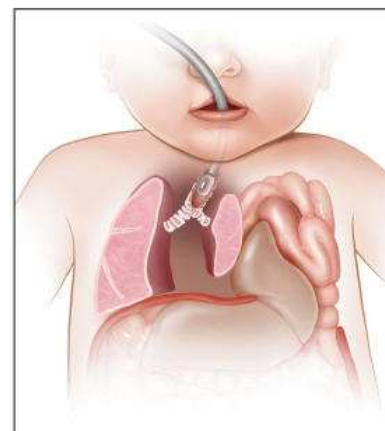
# KNOWING WHAT TO LOOK FOR MAY NOT BE EASY. KNOWING WHERE TO LOOK FOR HELP IS.

**Texas Children's Fetal Center™** is home to one of the nation's largest congenital diaphragmatic hernia (CDH) programs, with outcomes among the best in the country.

Ranging from moderate to severe cases of CDH, we offer fetal endoscopic tracheal occlusion (FETO), a breakthrough research protocol with potential to dramatically improve lung growth prior to birth. Coupled with outstanding multidisciplinary, postnatal surgical care, this treatment gives more babies with CDH a chance at a healthy life. As one of the first in the country to offer FETO, with one of the most experienced staffs in North America, we're proud to be on the leading edge of this revolutionary care.

Send us your toughest cases. We're known for delivering.

Learn more: [women.texaschildrens.org/fetal](https://www.women.texaschildrens.org/fetal) or 1-877-FetalRx



*FETO is a minimally invasive procedure in which a tiny balloon is inserted into the fetus to plug the trachea. The balloon is inflated, left in place for several weeks to allow the fetus' lungs to grow, then removed a few weeks prior to delivery.*



Pavilion  
for Women

# Language of Transducer Manipulation

## Codifying Terms for Effective Teaching

David P. Bahner, MD, RDMS, J. Matthew Blickendorf, MD, Marcia Bockbrader, MD, PhD, Eric Adkins, MD, Amar Vira, MD, Creagh Boulger, MD, RDMS, Ashish R. Panchal, MD, PhD, RDMS

There is a need for consistent, repetitive, and reliable terminology to describe the basic manipulations of the ultrasound transducer. Previously, 5 basic transducer motions have been defined and used in education. However, even with this effort, there is still a lack of consistency and clarity in describing transducer manipulation and motion. In this technical innovation, we describe an expanded definition of transducer motions, which include movements to change the transducer's angle of insonation to the target as well as the location on the body to optimize the ultrasound image. This new terminology may allow for consistent teaching and improved communication in the process of image acquisition.

**Key Words**—focused ultrasound; insonation; language; terminology; transducer manipulation; transducer motion; ultrasound education

Received February 12, 2015, from the Departments of Emergency Medicine (D.P.B., J.M.B., E.A., A.V., C.B., A.R.P.) and Physical Medicine and Rehabilitation (M.B.) and Center for Emergency Medical Services (A.R.P.), The Ohio State University Wexner Medical Center, Columbus, Ohio USA. Revision requested March 17, 2015. Revised manuscript accepted for publication May 12, 2015.

Address correspondence to David P. Bahner MD, RDMS, Department of Emergency Medicine, The Ohio State University, 750 Prior Hall, 376 W 10th Ave, Columbus, OH 43210 USA.

E-mail: david.bahner@osumc.edu

### Abbreviations

FAST, focused assessment with sonography for trauma; I-AIM, indication, acquisition, interpretation, and medical decision making

doi:10.7863/ultra.15.02036

Point-of-care ultrasound involves physician acquisition and interpretation of ultrasound images at the bedside to diagnose and direct patient care.<sup>1</sup> This process includes defining the indications for the examination, acquisition and interpretation of images, and using the results of the examination for medical decision making.<sup>2</sup> The rate-limiting step in the use of focused ultrasound by physicians is often the acquisition of images, as it involves manipulating the transducer and fine-tuning its position, in multiple directions, to display the ideal image.

There are little consistent data on the key maneuvers used to manipulate a transducer to acquire a high-quality image. In 1999, the American Institute of Ultrasound in Medicine published a technical bulletin, which described 5 basic movements, including sliding, rocking, tilting, rotating, and compression.<sup>3</sup> This nomenclature has been used; however, there is still a substantial inconsistency and overlap in terminology describing transducer motion.<sup>4-7</sup> Terms in common usage include move, slide, angle, fan, rock, and heel-toeing.<sup>4-7</sup> Other authors have compared transducer motions to aeronautic controls, describing motions as yaw, pitch, and roll.<sup>8</sup>

Prescriptive instructions to acquire ideal images are difficult without common terminology and understandable nomenclature. Consequently, transducer placement is illustrated on the body and correlated with an ideal image.<sup>4-8</sup> Since patient anatomy and conditions vary greatly, the illustrated transducer placement does not

always yield the ideal image. This factor is not an issue for experienced physicians, who naturally adjust transducer position to optimize the image. However, novice users are often challenged when the generated image is not as expected and compensate by moving the transducer in multiple planes simultaneously, resulting in repeated display of suboptimal images. This process may necessitate a demonstration of the correct adjustments from the instructor by removing the transducer from the learner's hand or "hand holding" in an attempt to obtain the ideal image. This practice inevitably affects the autonomy of the learners and the valuable aspect of hands-on learning time.

In this article, we describe a specific codification of terms for consistent, repetitive, and reliable teaching of ultrasound image acquisition. The key aspect of this technical innovation is distinguishing between movements that change the transducer's location on the body from those that affect the angle of insonation. This codification of transducer motions enables educators to instruct without removing the transducer from the learner's hand, subsequently improving the educational experience and enhancing knowledge retention. Prescriptive language further allows for quality improvement instruction from any location between operator and proctor, enabling opportunities for instruction from as near as the bedside to as far as a remote location.

## Redefining the Cardinal Transducer Motions

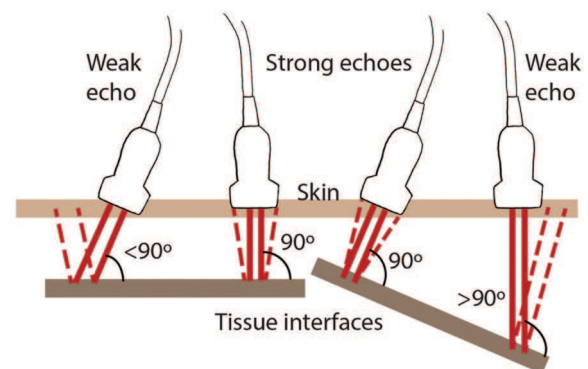
In 1999, the American Institute of Ultrasound in Medicine defined transducer motion, described as sliding, rocking, tilting, rotating, and compression.<sup>3</sup> However, these definitions do not distinguish between movements that change the transducer's location on the body from those that change the angle of insonation. The angle of insonation is defined as the angle of the ultrasound beam relative to the tissue or organ of interest (Figure 1). For example, a specular reflection produces the strongest echo signal by changing the angle of insonation so that the angle of incidence equals the angle of reflection (Figure 1).

For optimal imaging, maximizing the amplitude of a target's echo through transducer movement is critical. The amplitude of a target's echo detected by the transducer depends on the orientation of the target relative to the incident beam, the target's size, and its surface characteristics. The optimal image is obtained at a specular reflector, since the target's reflection to the transducer is maximized. A specular reflector is described by a perpendicular beam incident on a large, smooth, and flat interface, resulting in a reflected beam perpendicular to the surface. Although some of the

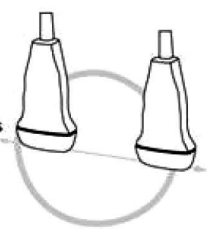
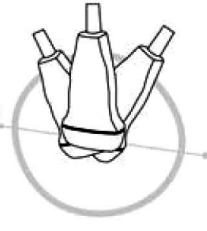
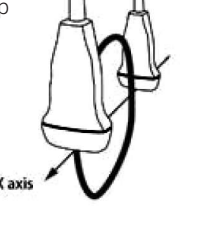
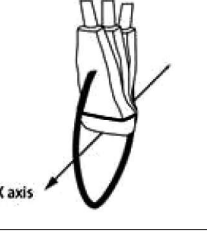
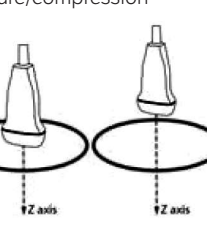
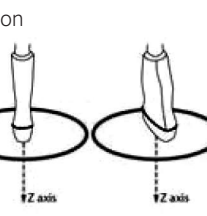
body's tissues behave as specular reflectors (ie, the diaphragm, the endometrial stripe, walls of blood vessels, and many solid organs), most echoes in the body arise from smaller interfaces that are neither perfectly smooth nor flat (diffuse reflectors).<sup>9–12</sup> Some tissues and organs can act as specular reflectors when imaged at a 90° angle of insonation, resulting in a strong echo and a hyperechoic image.<sup>12</sup> Due to the body's anatomy, these structures are oriented at many oblique angles relative to the skin surface, making visualization as a specular reflector difficult.<sup>10</sup> Approximating a specular reflection to produce the strongest echo signal is obtained by changing the angle of insonation, through transducer manipulation, so that the angle of incidence equals the angle of reflection (Figure 1).<sup>10,12</sup>

The redefined transducer motions described here expand on the previously published cardinal movements of the transducer, with a focus toward obtaining ideal images at specular reflectors. These are identified as slide, rock, sweep, fan, pressure/compression, and rotation and are related to the movements of the transducer in space (Table 1). These movements are primarily defined by the movement of the transducer across the body or by changing the transducer's angle of insonation. This difference is demonstrated in the comparison between the sliding and rocking movements of the transducer. Transducer movement in the long axis across the body with a consistent angle of insonation (90° to the target of interest) is called sliding (Table 1 and Video 1). This movement is commonly used when performing the focused assessment with sonography for trauma (FAST) scan on the Morison pouch and attempting to visualize the diaphragm by moving (sliding) the transducer cranially along the long axis of the transducer. In contrast, changing only the angle of insonation

**Figure 1.** Angle of insonation is defined as the angle of the ultrasound beam relative to the tissue or organ of interest. The strongest echoes are produced when the angles of incidence approach the angle of reflection.



**Table 1.** Redefined Set of Fundamental Transducer Motions

Slide		Motion in the long axis of the probe across the body with a consistent angle of insonation at 90° to the target
Rock		Motion in the long axis of the probe along a fixed point on the body while changing the angle of insonation away from 90°
Sweep		Motion in the short axis of the probe across the body with a consistent angle of insonation at 90° to the target
Fan		Motion in the short axis of the probe along a fixed point on the body while changing the angle of insonation away from 90°
Pressure/compression		Pressure on the probe into the body, compression of the body by applying force on the probe toward the patient's body
Rotation		Movement around the compression axis in a clockwise or counterclockwise direction

of the transducer in the long axis, with a fixed body position, is described as rocking (Table 1 and Video 2). This movement (rocking) is used in the FAST scan when visualizing the long axis of the pelvis with the nonindicator transducer edge held against the pubis and the angle of insonation changed toward the pelvis to visualize the complete bladder in the long axis.

The evaluation of the body by moving the transducer in the short axis also has a similar set of descriptors: sweeping and fanning. Transducer movement in the short axis across the body with a consistent angle of insonation (perpendicular) is called sweeping (Table 1 and Video 3). Transducer movement in the short axis with a fixed position on the body but changing only the angle of insonation is called fanning (Table 1 and Video 4).

Different from these definitions are the final movements of the transducer, which are defined by the relationship of the transducer footprint to the body. This relationship can be either a consistent position of the transducer footprint to the body (with application of pressure on the transducer) or a rotation of the transducer footprint in relation to the body. Compression/pressure is defined as pressure being applied on the transducer, with the transducer footprint at a fixed position, causing the transducer to move into the body by applying pressure on the tissue (Table 1 and Video 5). This maneuver is commonly used to displace bowel gas or remove a contact artifact. It is also used clinically to compress veins, determine elastography, and assess the tissue response to pressure. In contrast, rotation is movement around the axis of the transducer's footprint (Table 1 and Video 6). A clock face can be used to describe rotation, with the indicator edge directed cephalad, which is designated 12 o'clock. Rotations can be made in the clockwise or counterclockwise direction around the fixed axis. For example, rotation of the transducer 90° clockwise is a motion of turning the leading edge from 12 o'clock to 3 o'clock.

## Application of Redefined Cardinal Movements

The act of deliberate scanning means moving the transducer in one direction at a time to achieve certain elements of a high-quality scan and then progressing to the next movement in response to the generated image. This act is the psychomotor skill that each operator masters to obtain the desired ideal image. Although transducer motion is the primary path to achieving these high-quality images, a proper and consistent language can assist with pattern recognition, psychomotor skill acquisition, and improved communication between operator and proctor. This ability to acquire



high-quality images occurs through a consistent experience in which the operator is able to recognize the plane of imaging and the correct plane required and then, through consistent feedback from expert operators, learns maneuvers that will allow for the optimal generation of images. For example, pattern recognition and psychomotor scanning can help operators if they realize that after a target is centered on the screen by sliding or rocking, the only motions required for an ideal image to be obtained are sweeping, fanning, and rotating the transducer into the correct plane.

The use of these redefined cardinal movements can allow for a systematic approach to interrogating a space of interest. A cohesive application of these cardinal movements can enhance education by coordinating the intended goal of scanning and clarifies bedside ultrasound teaching, as operator and educator are consistent in their communication.

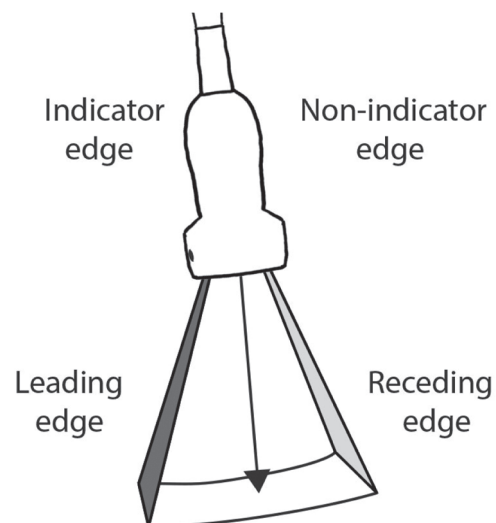
The use of these redefined cardinal transducer movements has been formalized as part of the I-AIM (indication, acquisition, interpretation, and medical decision making) educational model used at The Ohio State University.<sup>2</sup> In this training program, image acquisition is optimized through a consistent teaching practice and improved communication. For consistency in our ultrasound training, the displayed images all have the indicator dot on the left. The left side of the image corresponds to the transducer's indicator edge and is referred to as the leading edge, whereas the opposite is the receding edge (Figure 2). Using this rule of image orientation, the transducer motion of "sliding" brings partially visualized images at the leading or receding edge into full view. Sliding moves the target structure from side to side on the screen. When the operator performs a "rocking" motion, this functions to center structures from the leading to receding edges as tilted images around a fixed focal point. In contrast, "sweeping" functions to interrogate a structure from side to side or end to end by bringing structures into and out of the screen. Similarly, "fanning" can be used to interrogate a structure side to side like sweeping but does so around a fixed focal point and varies the angle of insonation around a specified target. Finally, the transducer can be rotated around a fixed focal point clockwise or counterclockwise to image structures in a 360° fashion, moving from long to short axes and through many oblique axes to optimize the image.

The scanning protocol developed from the I-AIM model begins with macro movements (defined as >3–5 cm) to survey the area and then continues to finer movements for image optimization after the target is identified. This survey of the area begins by using a short-axis macro sweep over the area of interest to assess for viable acoustic win-

dows, identify target structures, and observe the returning ultrasound signatures. From these macro sweeps, landmarks are identified, and the operator determines whether the anatomy of interest is fully visualized and in the correct intended plane. If not, the transducer is moved in a long-axis slide to center the intended anatomy on the screen and bring it into full view. A long-axis rocking motion is then used to center the anatomy of interest, and the angle of insonation is adjusted in the short axis by micro (<3 cm) fan motions, which optimize the specular reflection. Isolated rotation from this point displays the anatomy of interest in long, short, and many oblique axes without also altering the location of the desired anatomy on the screen or the strength of the echo signal.

Application of these rules, while using consistent language, enables educators to formulate prescriptive instructions to obtain ideal images. For example, learners seeking to visualize the Morison pouch during a FAST examination are instructed to place the patient in the supine position and use a curvilinear transducer with the depth set to about 14 cm. Place the transducer, with the beam oriented parallel to the bed, along the right anterior axillary line at about the eighth or ninth rib space with the indicator edge oriented at 12 o'clock. This position should bring the right lobe of the liver into view. As the transducer is swept posteriorly, the gallbladder, the great vessels, and the right kidney are displayed from anterior to posterior. When the

**Figure 2.** Nomenclature of the image displayed for point-of-care ultrasound imaging using the I-AIM teaching model. The indicator is on the left for all images, with the leading edge associated with the indicator and the receding edge on the opposite side.



hepatorenal interface is visualized, sweep the transducer to bring this interface into full view and rock to center the hepatorenal space on the screen. Rotate the transducer from the 12-o'clock to the 10-o'clock position to eliminate rib shadows, as the 10-o'clock position (leading edge toward the bed) approximates the angle of the ribs relative to the axillary line. Adjust the depth and gain appropriately to optimize the image, and save a still of the ideal image.

## Discussion

Point-of-care ultrasound involves acquisition and interpretation of ultrasound images, which are often challenging to obtain for novice users. Providing prescriptive instructions to acquire ideal images is difficult without common terminology, a rationale for optimal transducer placement, and understandable nomenclature used by both learners and educators. Without a clear communication channel, this process often leads to instruction, which involves removing the transducer from the hand of a novice user. It further makes it difficult for novice users to gain the needed framework and skills for troubleshooting suboptimal images.

In this technical innovation, we describe the use of a redefined, clarified set of cardinal transducer manipulations focused on the key aspect of the angle of insonation and how it relates to improved ultrasound image acquisition. Learners gain a framework for transducer adjustment and troubleshooting to optimize a suboptimal image by moving the transducer in clear directions toward obtaining specular images of targeted tissue. Because the transducer never leaves a learner's hand, "scanning muscle memory" may be developed by repeatedly following standard instructions for transducer movement while observing how the image is altered. Because these terms describe movement according to axes of the transducer and not the body, they can be used interchangeably regardless of the transducer used or examination performed.

These transducer motions are those that have been integrated into the I-AIM educational model at one institution.<sup>2</sup> The use of this method has been successful in teaching multiple diverse learners of the art of point-of-care ultrasound. However, it is clear that other methods to codify transducer motions exist. It is our opinion that ambiguity around these terms may delay optimal learning of how to scan effectively. Future studies could determine how current operators codify the various transducer motions to determine a consensus on terminology and descriptors. As more medical schools begin to train undifferentiated future physicians how to use ultrasound, there will need to

be a coordination of terms, techniques, and teaching styles. Ultimately, a standard codification could help clarify the acquisition of images and assist in education.

The codification of transducer motions and a standardized technique for description may also assist with point-of-care ultrasound in venues outside the hospital setting. The World Health Organization projects that radiography and ultrasound, whether combined or separate, will satisfy two-thirds of all imaging needs in the developing world.<sup>13</sup> As the use of ultrasound expands to austere environments, assistance with remote instruction of novice users may become an important part of patient care.<sup>14–17</sup> Clearly, standardized terms and educational methods may assist in remote ultrasound instruction where the operator is fully responsible for moving the transducer in performing the examination.

In conclusion, there is a need for consistent, repetitive, and reliable terminology to describe the basic manipulations of the ultrasound transducer. In this technical innovation, we describe an expanded definition of transducer motions and the application of the redefined cardinal motions for education. This new terminology may allow for consistent teaching and improved communication in the process of image acquisition.

## References

1. Moore CL, Copel JA. Point-of-care ultrasonography. *N Engl J Med* 2011; 364:749–757.
2. Bahner DP, Hughes D, Royall NA. I-AIM: a novel model for teaching and performing focused sonography. *J Ultrasound Med* 2012; 31:295–300.
3. American Institute of Ultrasound in Medicine. AIUM technical bulletin: transducer manipulation. *J Ultrasound Med* 1999; 18:169–175.
4. Gaspari RJ, Fox JC, Sierzenski PR. *Emergency Ultrasound: Principles and Practice*. 1st ed. Philadelphia, PA: Elsevier Mosby; 2006.
5. Levitov AB, Dallas AP, Slonim AD. *Bedside Ultrasonography in Clinical Medicine*. 1st ed. New York, NY: McGraw-Hill; 2011.
6. Cosby KS, Kendall JL. *Practical Guide to Emergency Ultrasound*. 1st ed. Philadelphia, PA: Lippincott Williams & Wilkins; 2006.
7. Ma OJ, Mateer JR, Blaivas M. *Emergency Ultrasound*. 2nd ed. New York, NY: McGraw-Hill; 2007.
8. Noble VE, Nelson B. *Manual of Emergency and Critical Care Ultrasound*. 2nd ed. New York, NY: Cambridge University Press; 2011.
9. Curry RT, Bates Tempkin B. *Ultrasonography: An Introduction to Normal Structure and Functional Anatomy*. Philadelphia, PA: WB Saunders Co; 1995.
10. Zagzebski J. *Essentials of Ultrasound Physics*. St Louis, MO: CV Mosby Co; 1996.
11. Hagen-Ansert S. *Textbook of Diagnostic Ultrasonography*. 5th ed. St Louis, MO: CV Mosby Co; 2001.

12. Rumack CW, Wilson SR, Charboneau JW, Johnson JM. *Diagnostic Ultrasound*. 3rd ed. Philadelphia, PA: Elsevier Mosby; 2005.
13. Meir A, Rubinsky B. Distributed network, wireless and cloud computing enabled 3-D ultrasound: a new medical technology paradigm. *PLoS One* 2009; 4:e7974.
14. Otto C, Hamilton DR, Levine BD, et al. Into thin air: extreme ultrasound on Mt Everest. *Wilderness Environ Med* 2009; 20:283–289.
15. Nelson BP, Chason K. Use of ultrasound by emergency medical services: a review. *Int J Emerg Med* 2008; 1:253–259.
16. Brooks AJ, Price V, Simms M. FAST on operational military deployment. *Emerg Med J* 2005; 22:263–265.
17. Sargsyan AE, Hamilton DR, Jones JA, et al. FAST at MACH 20: clinical ultrasound aboard the International Space Station. *J Trauma* 2005; 58:35–39.